

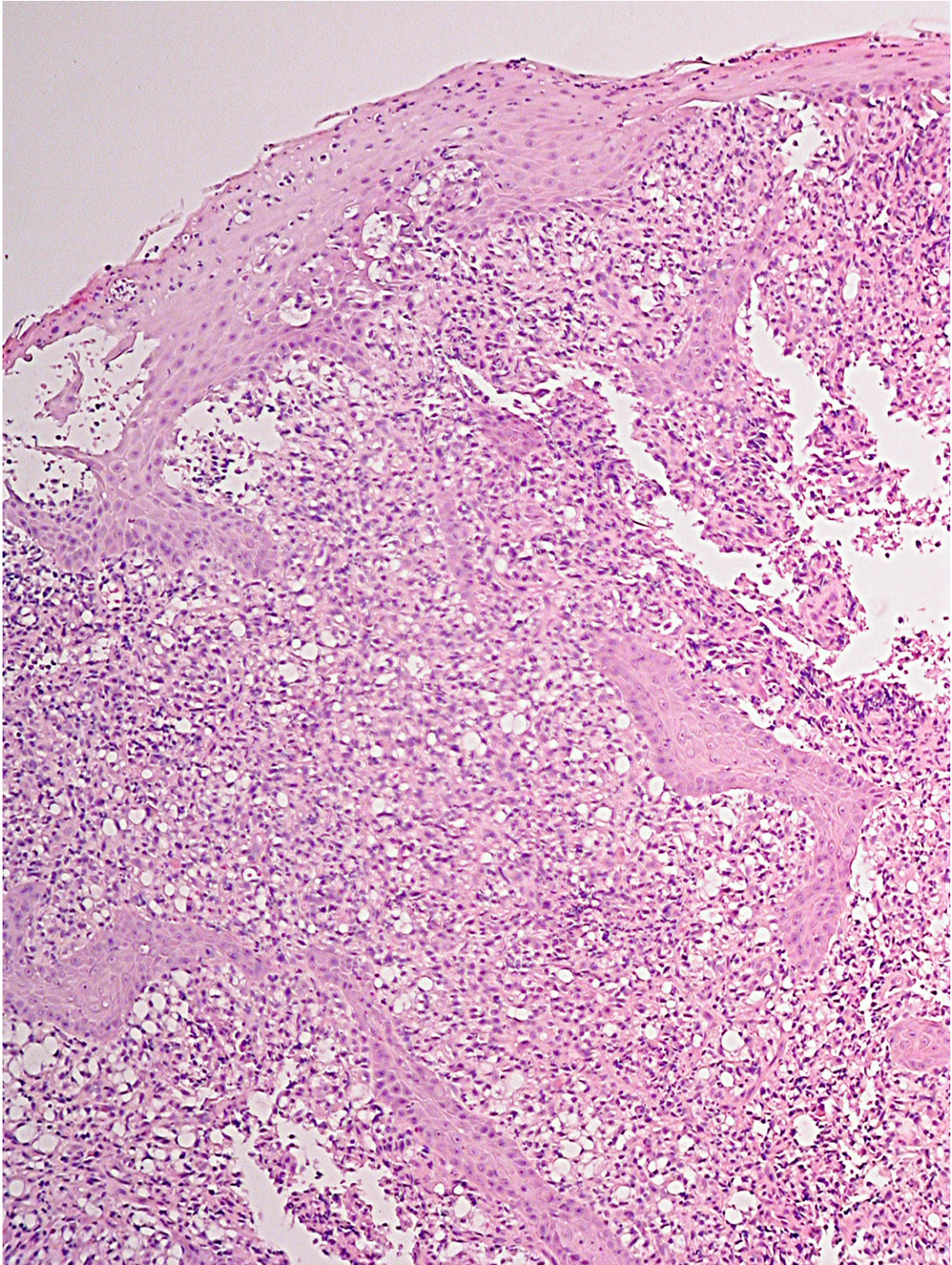
# Slide Seminar

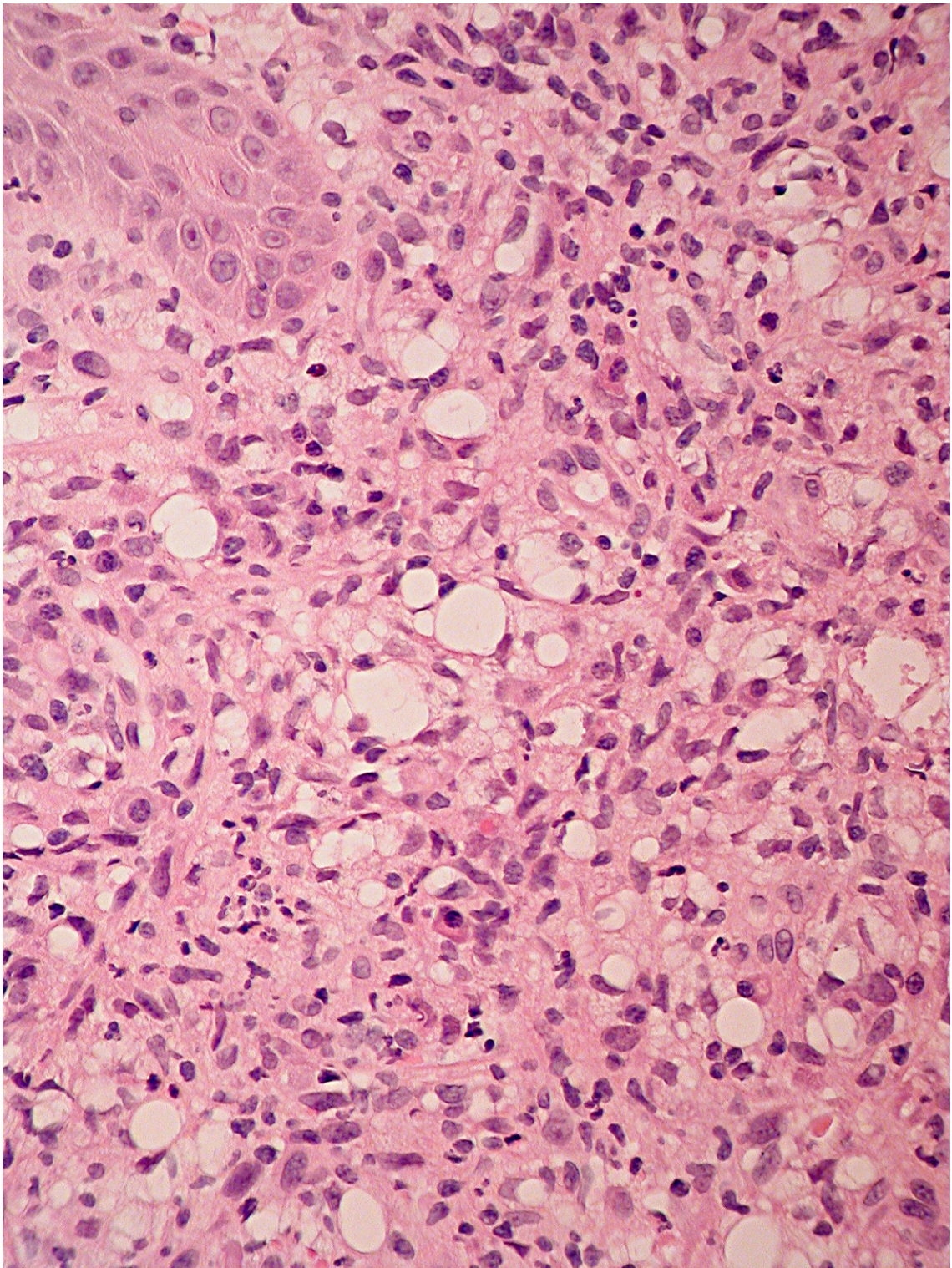
## Oral Pathology

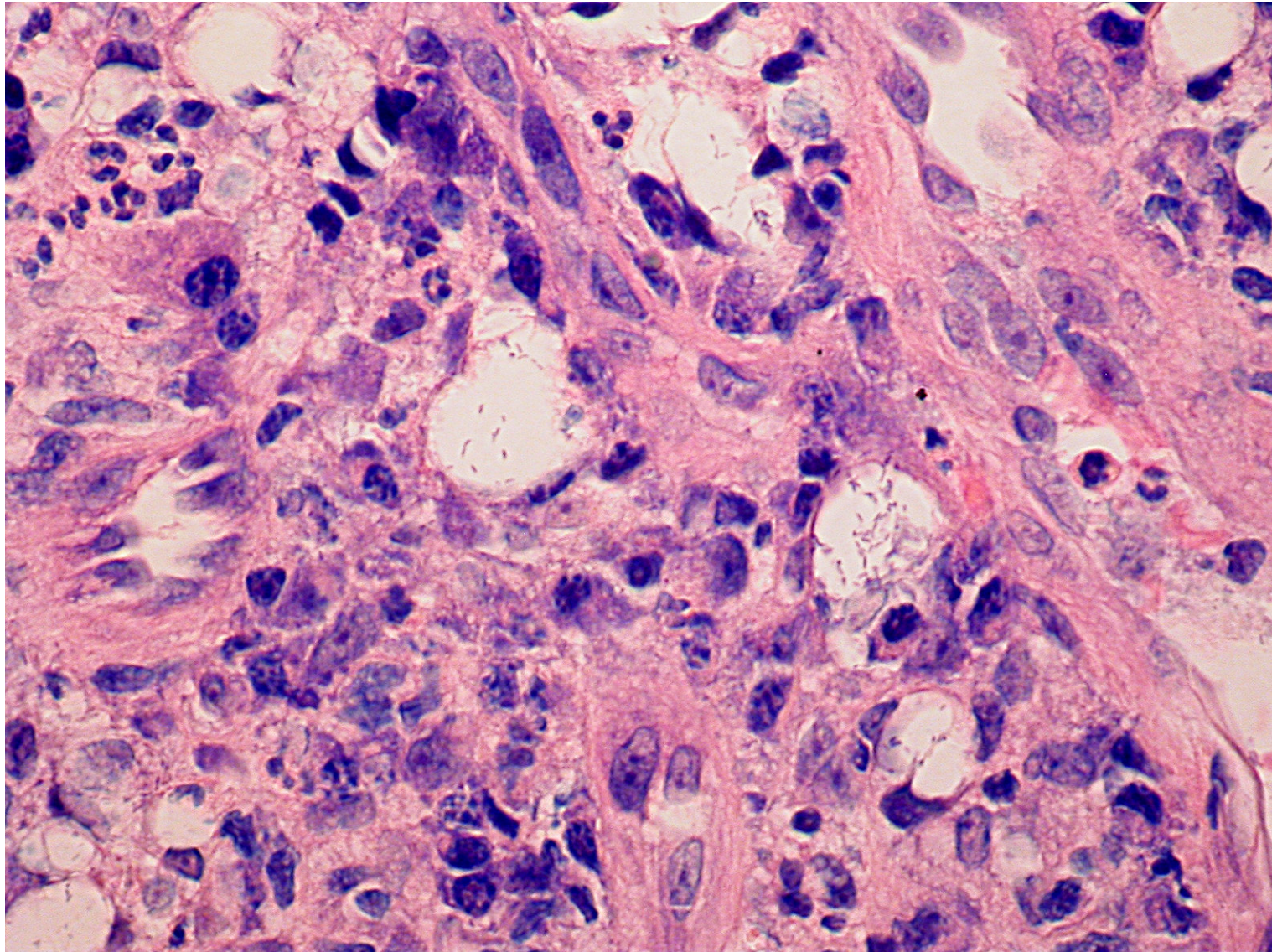
Case 2

Male 29y

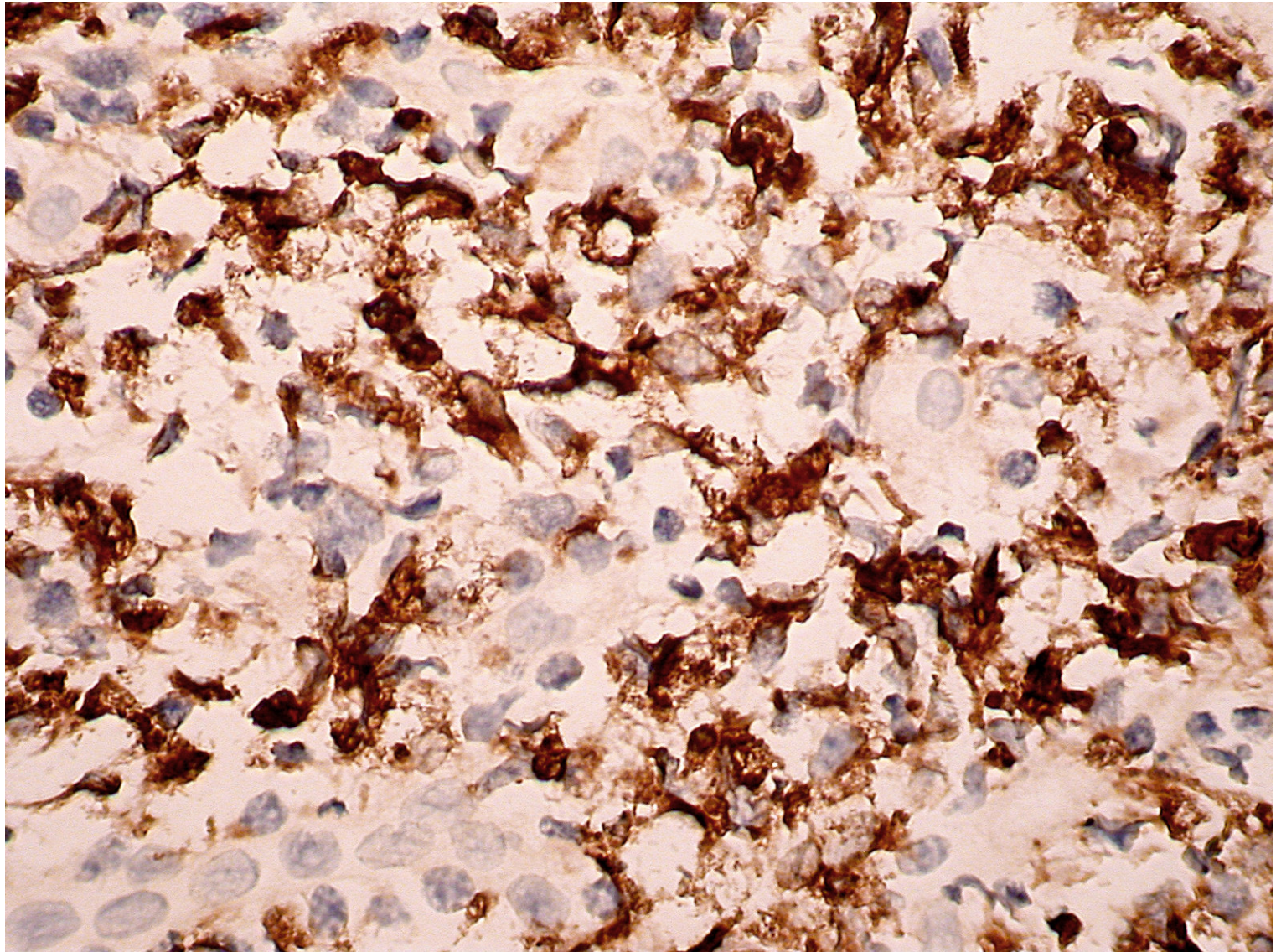
1 year history of ulcerated lesion soft  
palate, presumed SCC.



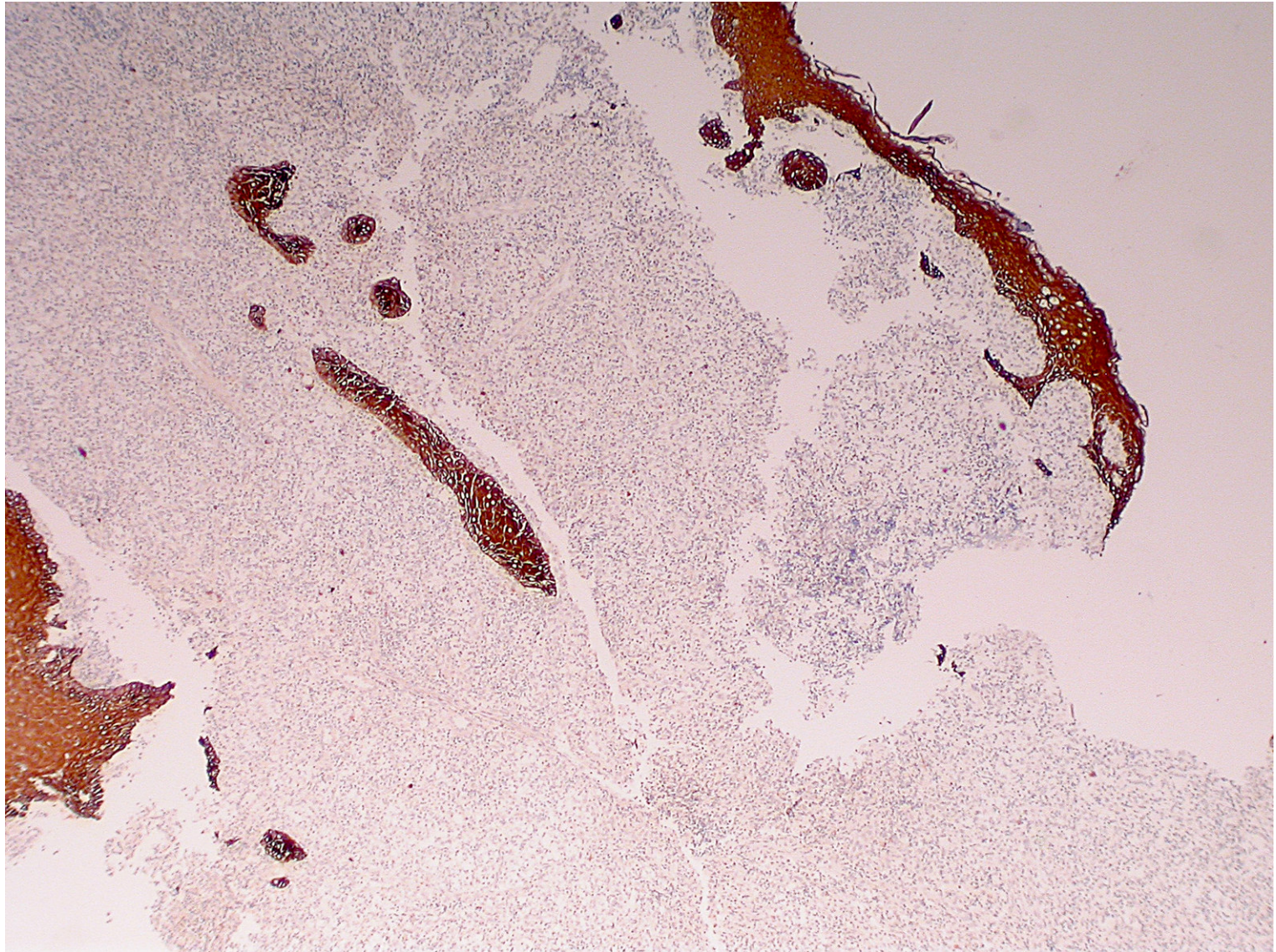




Giemsa



CD68



CK14